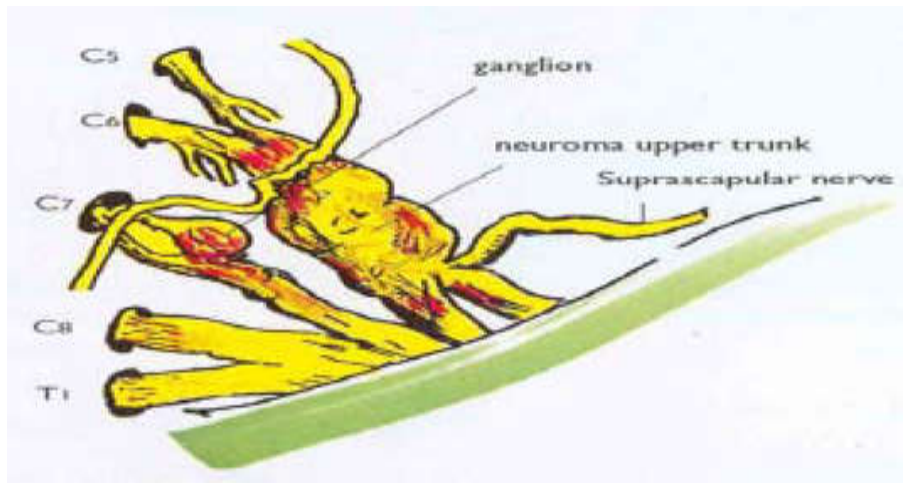
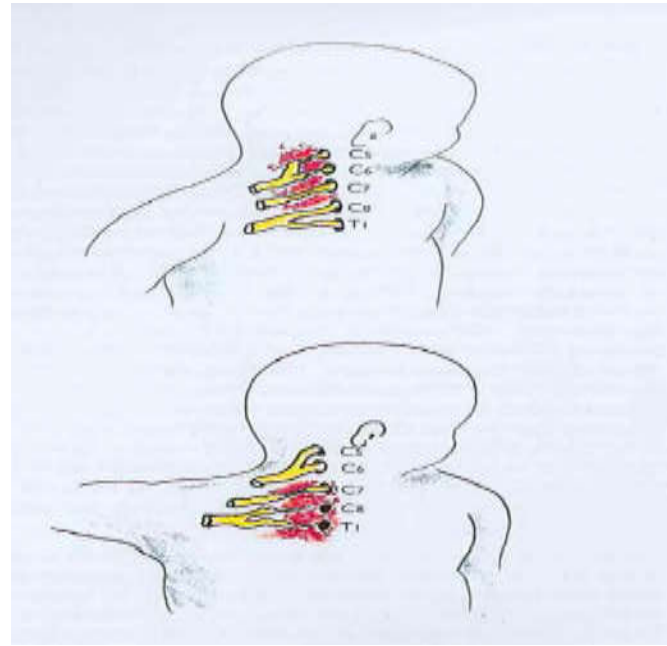
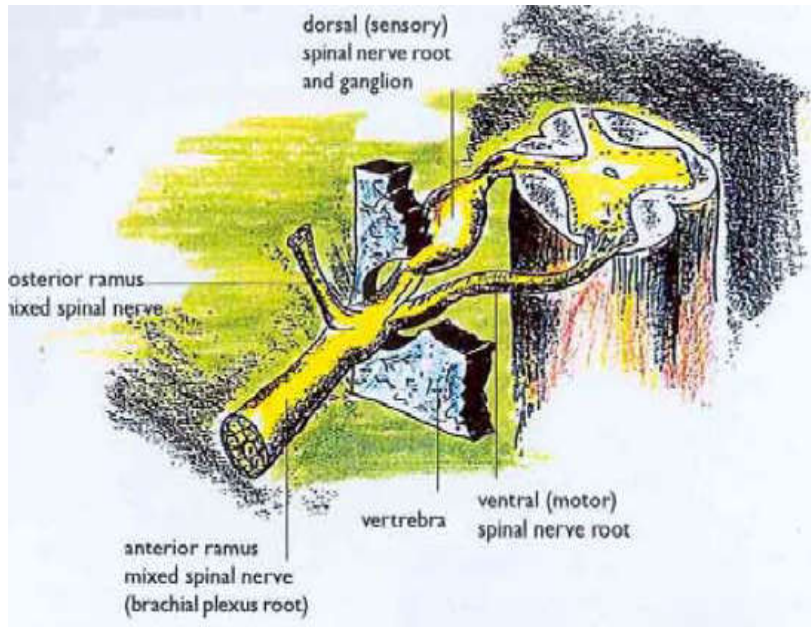


OBSTETRICAL BRACHIAL PLEXUS PALSY

KHOA BỔNG – CHẤN THƯƠNG CHỈNH
HÌNH

OBSTETRICAL BRACHIAL PLEXUS PALSY

- OBPP results from trauma at birth.
- It is more common in large babies (over 4000 grams)
- It is a stretch injury affecting many different nerves, to variable degrees, within the brachial plexus.
- It occurs in an average of 1 to 1,000 births
- At least 70% recover without treatment.
- The brachial plexus anatomy is never constant, therefore, conclusions as to injury extent and location without actually seeing the lesion are only assumptions which may or may not be correct.



- **Abstract**

- The authors review the cases of 116 infants treated consecutively for birth-related brachial plexus injuries. Twenty-eight infants with upper brachial plexus lesions who showed no neurological improvement by 4 months of age were selected for early surgical reconstruction (at a mean age of 5 months). Neurological improvement of the affected arm was observed in more than 90% ($p < 0.05$) of the children examined longer than 9 months after brachial plexus reconstruction. A conservatively managed control subgroup of 44 children, first examined at less than 3 months of age, demonstrated neurological improvement by 4 months of age and continued to show improvement at 1 year of age. Early surgical reconstruction is recommended for infants with birth-related upper brachial plexus injury who show no neurological improvement by the age of 4 months.
- August 1993 / Vol. 79 / No. 2 / Pages 197-203

Evaluation and diagnosis

- *DUCHENNE-ERB*: C5 - C6 good hand, bad shoulder
- *KLUMPKE-DEJERINE*: C8 - D1 bad hand ,some shoulder
- *REMAK*: C7
- **Total** : C5-C6-C7-C8-D1

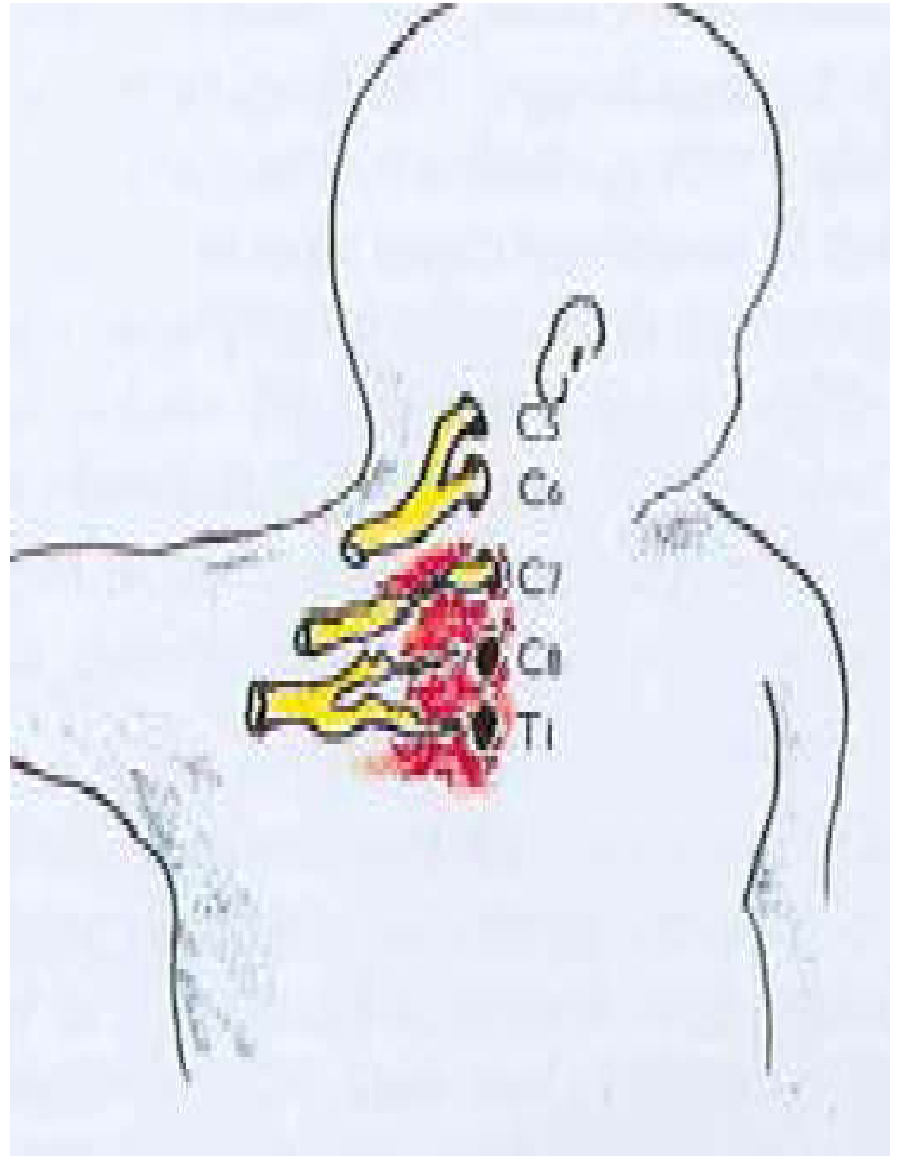
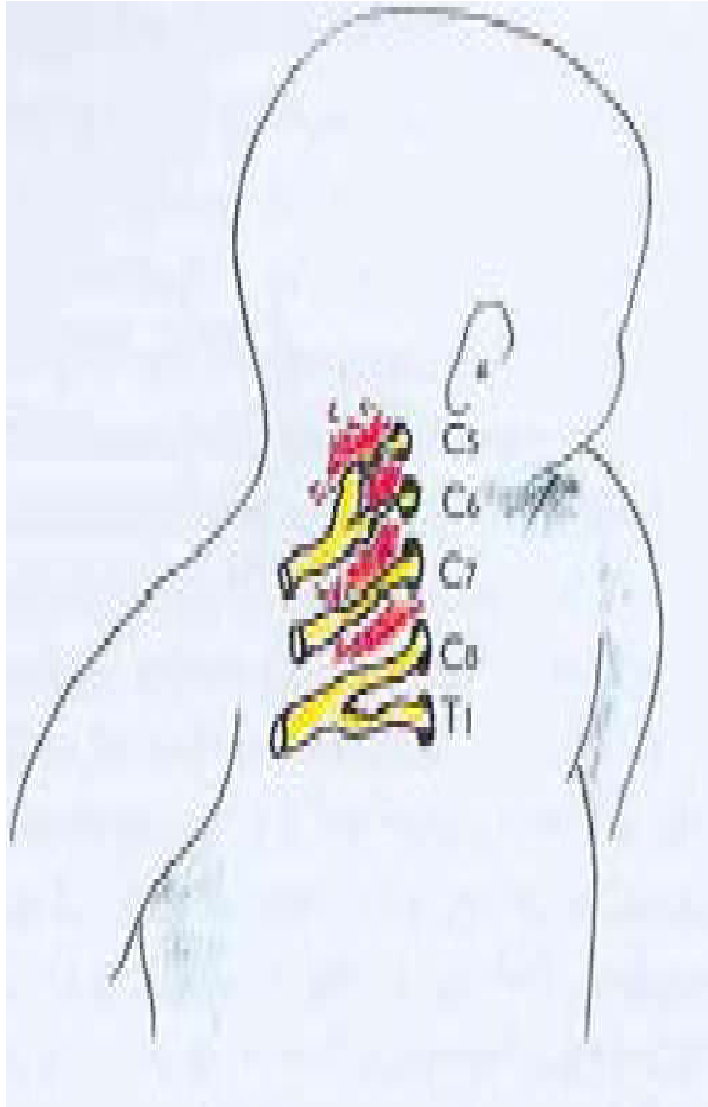


Tabla 1
GENERAL EVALUATION: PLEXUS INJURY

1. Shoulder	Abduction	Anterior flexion External rotation
		Internal rotation
2. Elbow	Flexion	Extension
3. Wrist	Flexion	Extension
4. Thumb	Flexion	Extension
5. Finger	Flexion	Extension

Sequence to follow when evaluation a brachial plexus injury. Simply circle the activity noted. Is it an upper or a total/lower plexus injury

Table 2.

MUSCLE GRADING SYSTEM

* No Contraction	M0	
* Contraction, No Motion	M1	
* Contraction, Motion only when gravity is eliminated		M2
* Contraction, complete motion against gravity		M3

Modification of the MC scale according to Gilbert and Tassin 1987

Table 3.

EVALUATION : UPPER PLEXUS

			M0 - M3 / Date
• Shoulder	Abduction	Deltoid/.....
• Elbow	Flexion	Biceps/.....
• Wrist	Extension	ECRB/.....
		ECRL/.....
		ECU/.....

Upper plexus injuries, evaluation to decide: wait or surgery?

Isolated muscle strength for biceps and deltoids needs to be recorded. Method (M0-M3) scales and date must be included. Specific motion in at least the three anatomical areas listed should be evaluated.

- Two questions must be answered:
 - Is the problem an upper plexus or a total/lower plexus?
 - The hand distinguishes upper plexus from total plexus injuries.
 - Upper plexus problems have a good hand and a poor or absent shoulder function.
 - Total/lower plexus problems display a poor hand with flail wrist and no finger flexion.
 - Should one recommend waiting or surgery?

On indications for surgery

- Total/lower plexus: Early surgery (2-3 months)
- Upper plexus :
 - biceps M0 at 3 months, proceed with surgery.
 - some biceps at 3 months, wait
 - if biceps is not complete or normal by 5 months, proceed with surgery
- It is better to operate on a baby that could have recovered equally without surgery, than to allow a baby to end up with a poor result for not performing surgery.
- Errors in commission, performing surgery in doubtful cases does not worsen the situation.
- Errors in omission, not performing surgery in doubtful cases, have resulted in irreparable losses, a worse situation.
















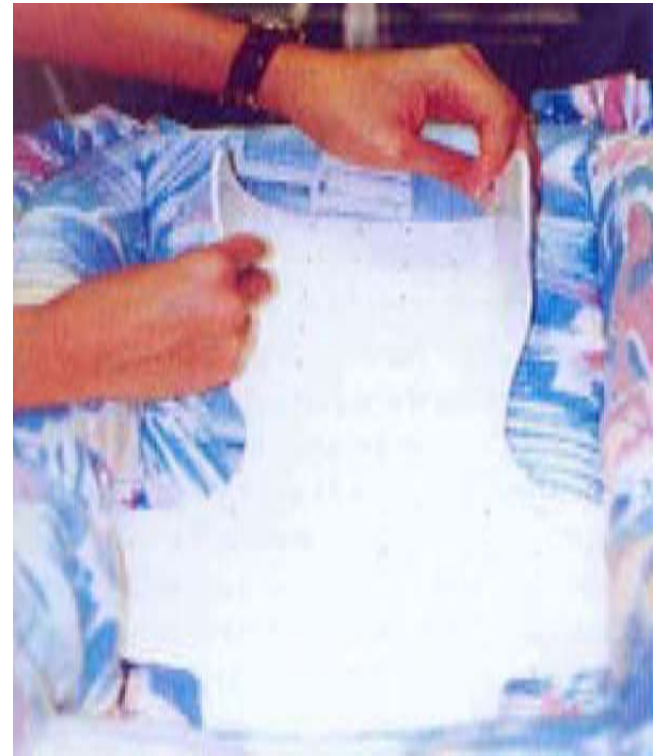
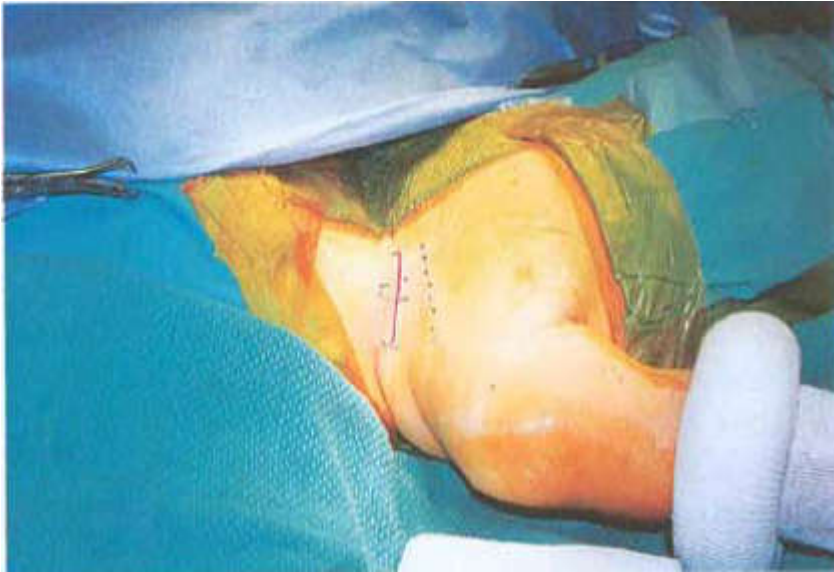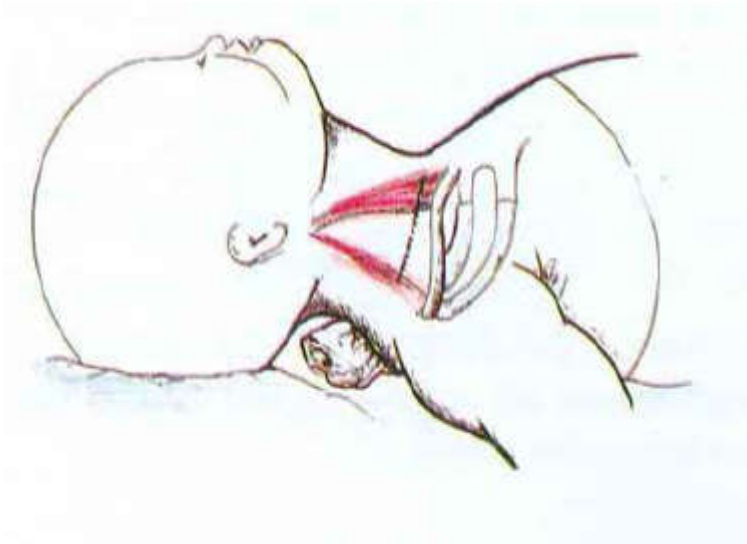
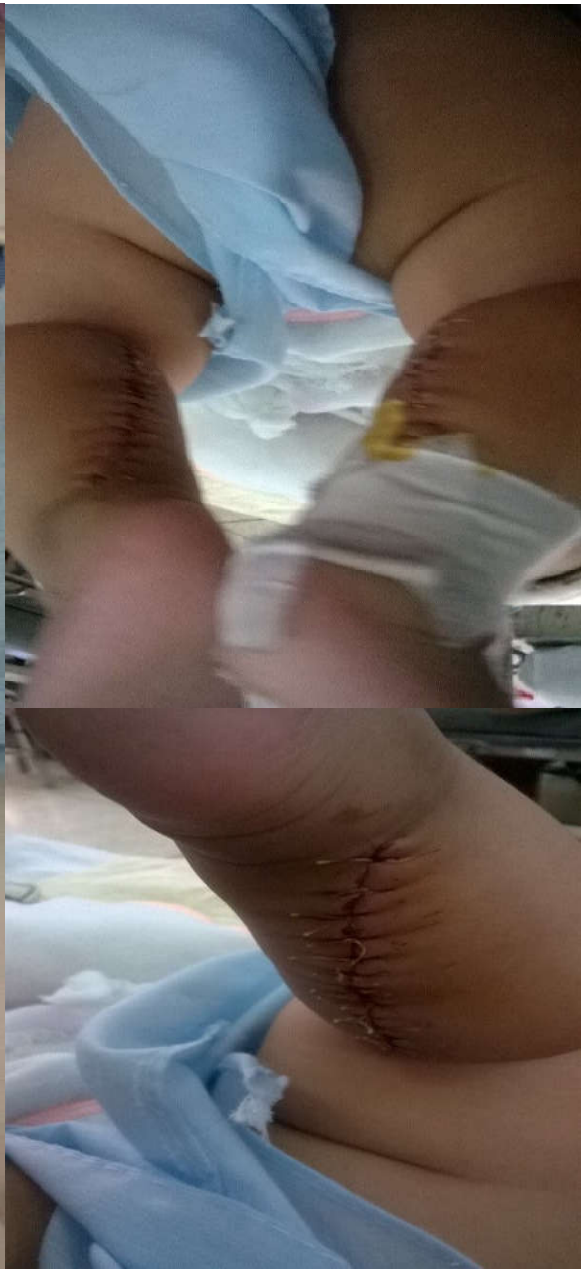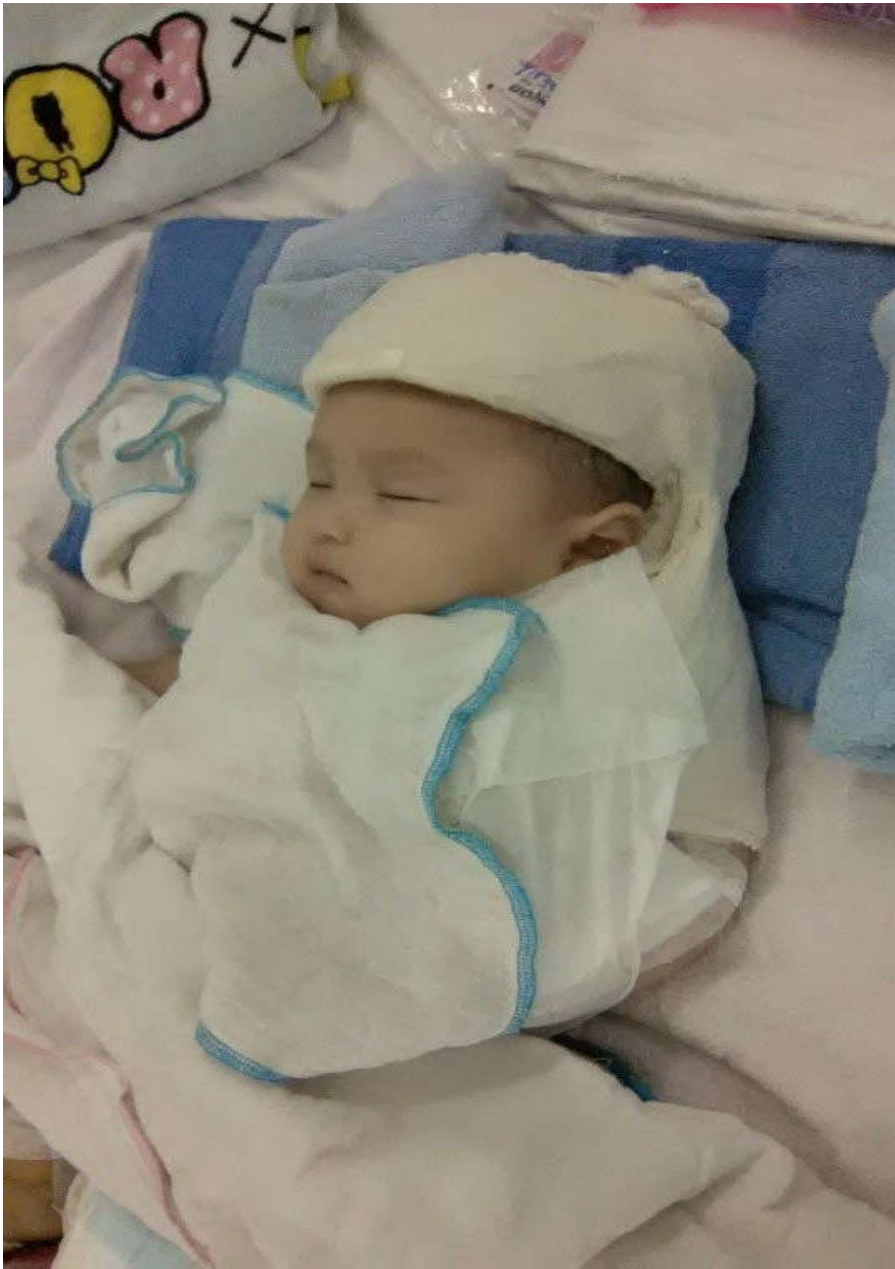	II	III	IV
Active abduction	 inferior to 30°	 30° to 90°	 superior to 90°
External rotation	 0°	 inferior to 20°	 superior to 20°
Hand to nape of neck	 impossible	 difficult	 easy
Hand to back	 impossible	 S ₁	 T ₁₂
Hand to mouth	 clear	 small clear	

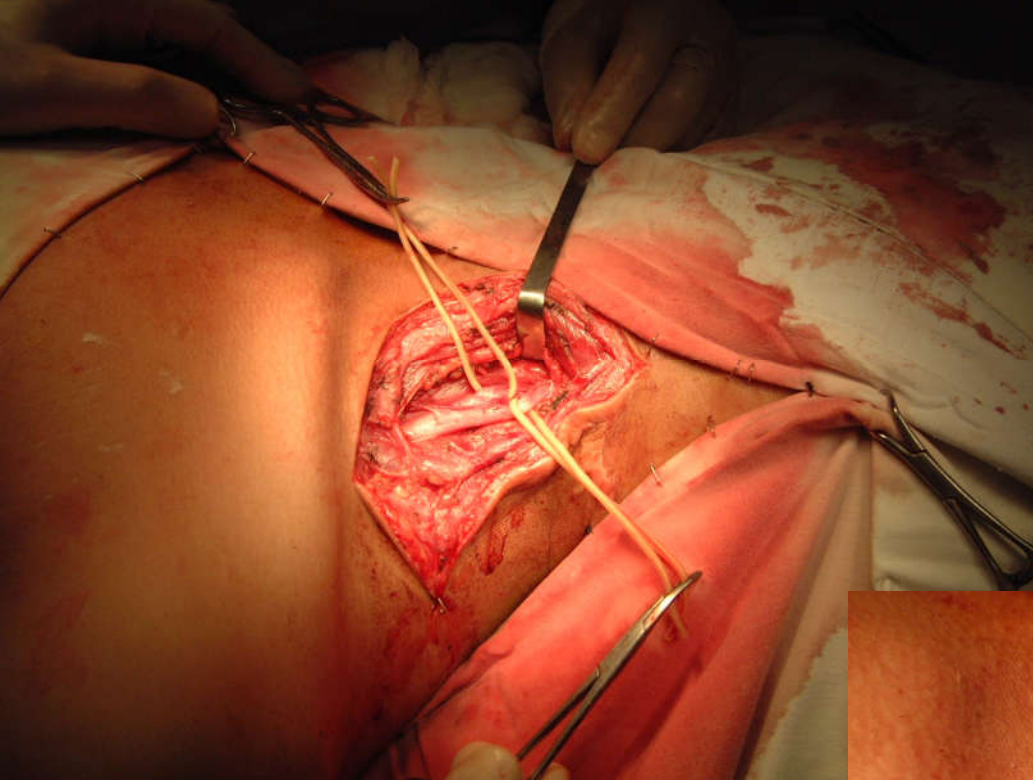
TABLE 5

Mallet's classification of function in obstetrical brachial plexus palsy. Grade 0 (not shown) is movement in the desired plane and Grade V (not shown) is full, normal, movement.

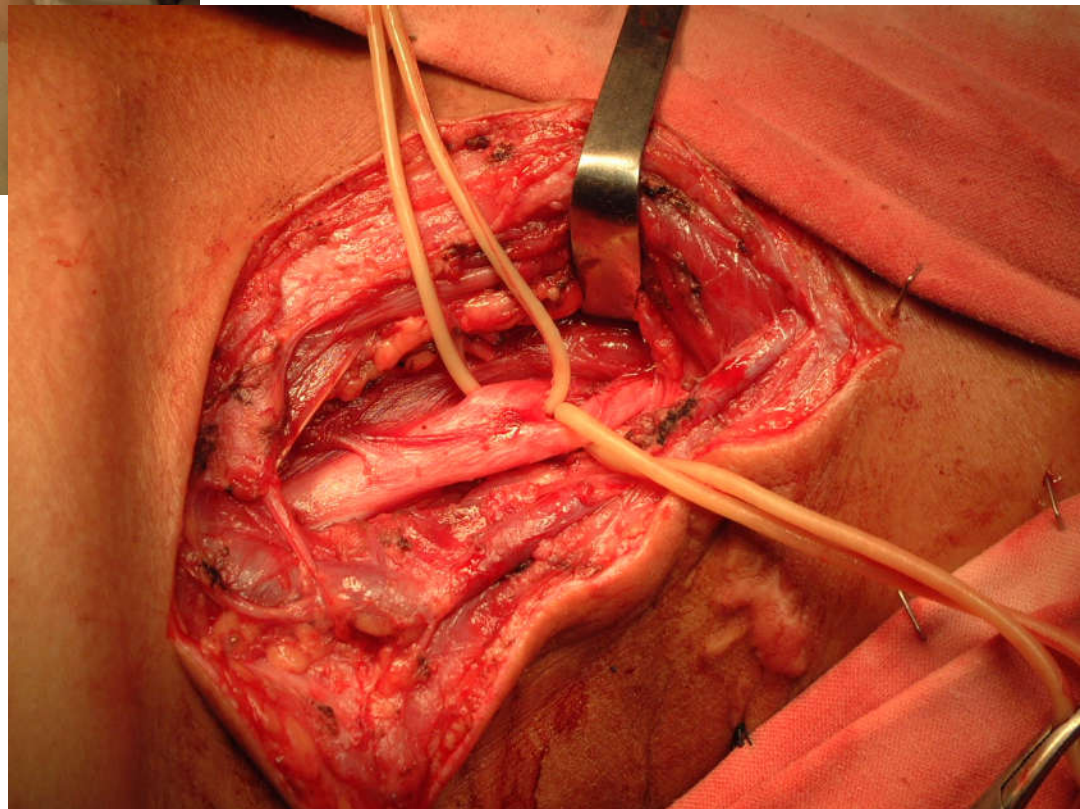
From Gilbert A, WB Saunders Company, 1993, p 579.)



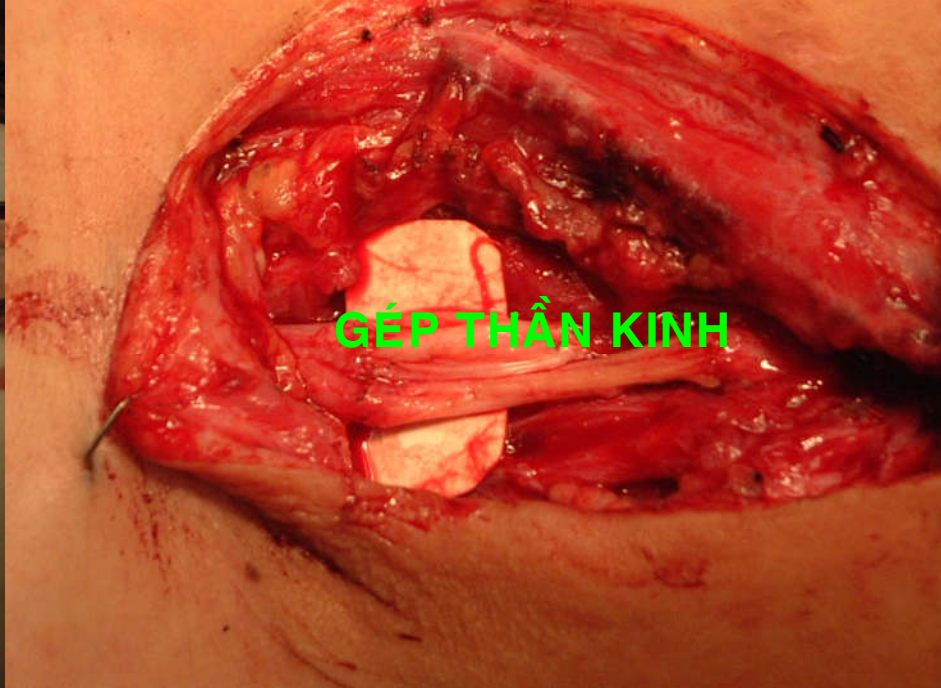



THĂM SÁT THẦN KINH



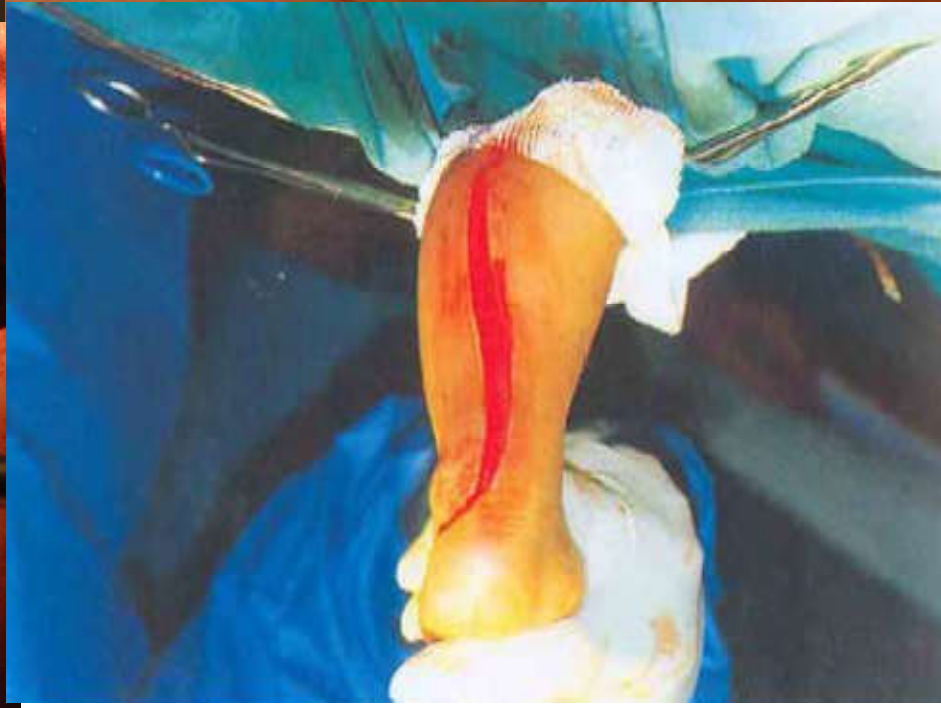
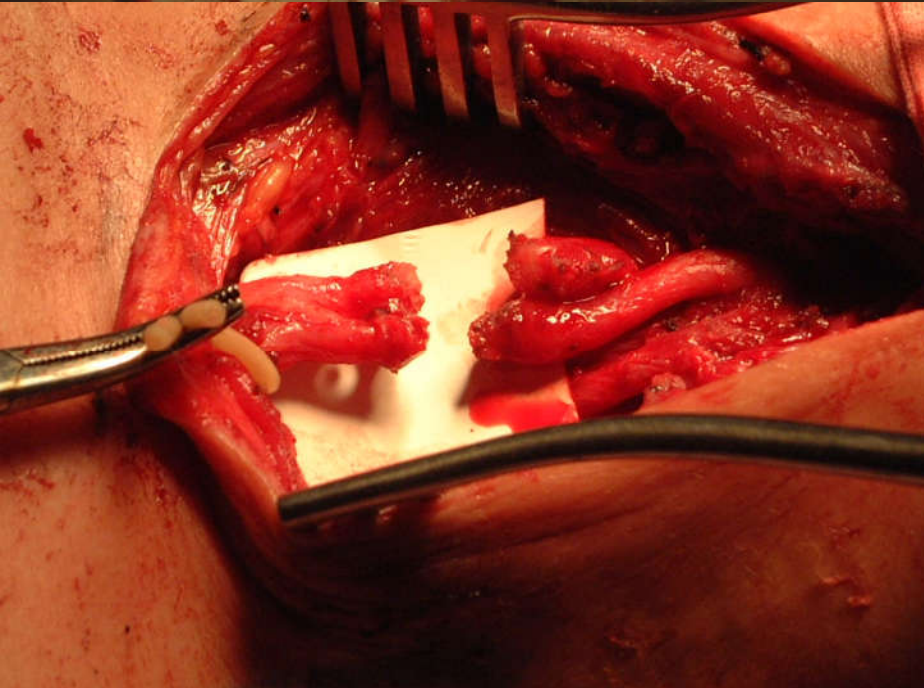
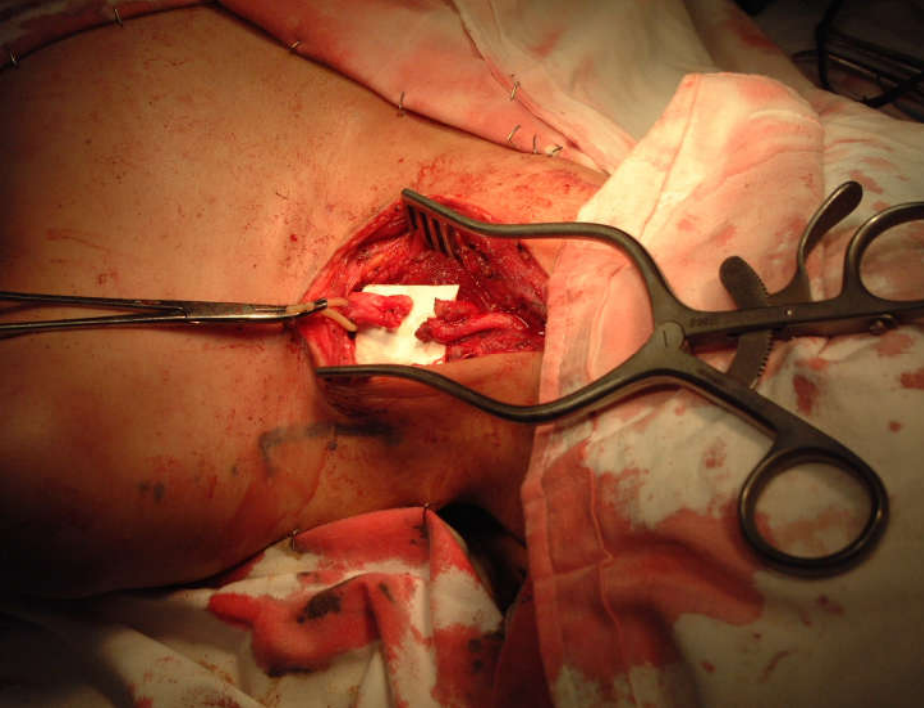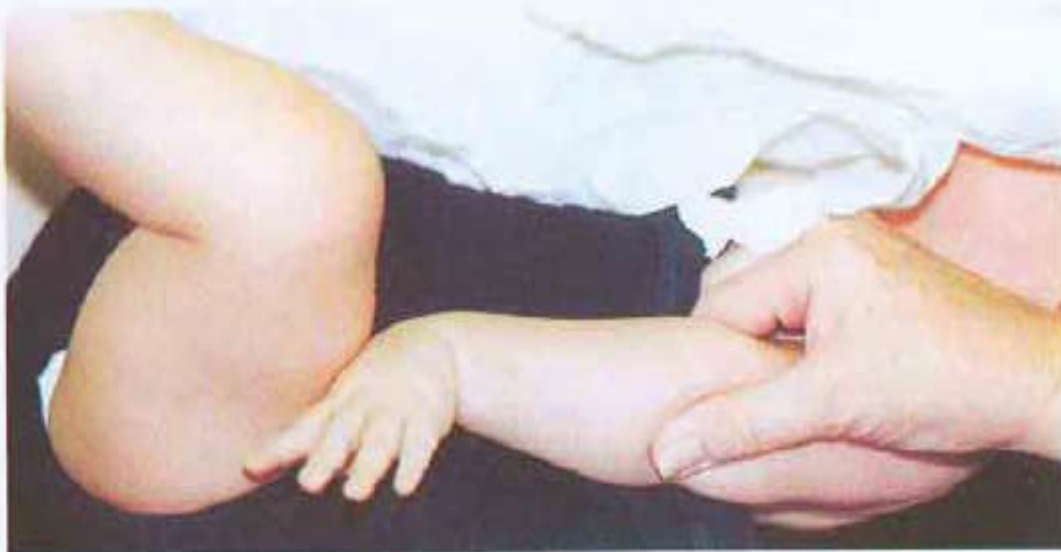




FIGURE 18

Wrist evaluation: Absent wrist extension with normal C7. Evaluation at 3 months. No wrist extension, finger and thumb extend with tenodesis effect. Elbow: no flexion, biceps M0

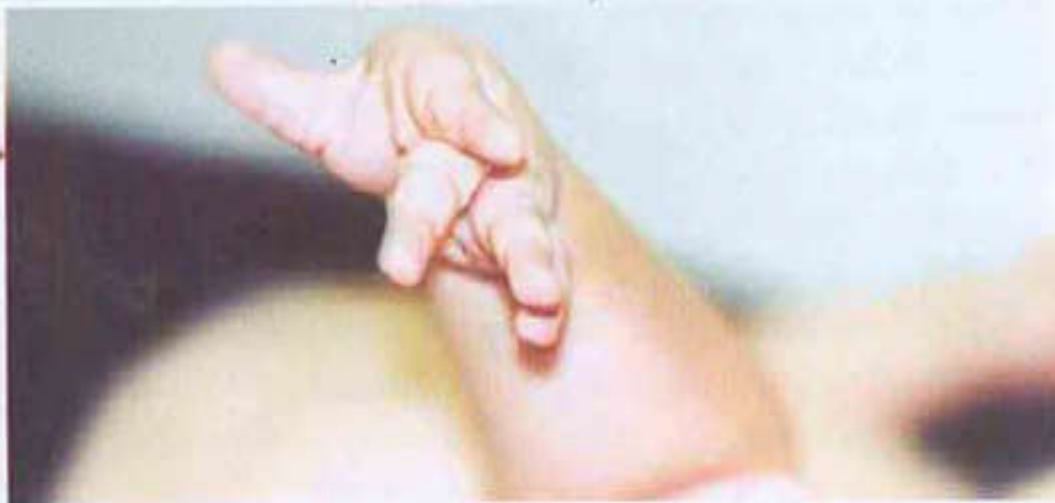

FIGURE 11

Evaluation at 6 months. Total plexus, "bad hand, poor shoulder". Shoulder: Weak abduction, no external rotation, good internal rotation. Deltoid M1. Notice lid lag indicative of Horner's syndrome.

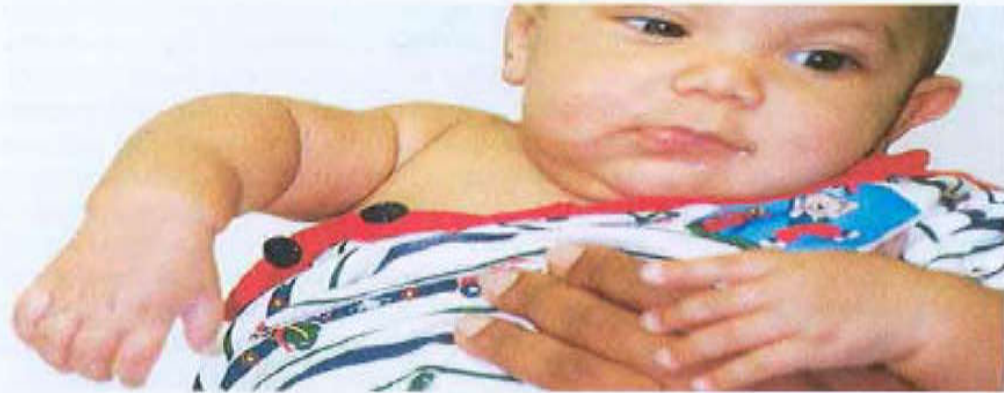

FIGURE 12

Elbow: No flexion, very weak extension Biceps M0, triceps M2.

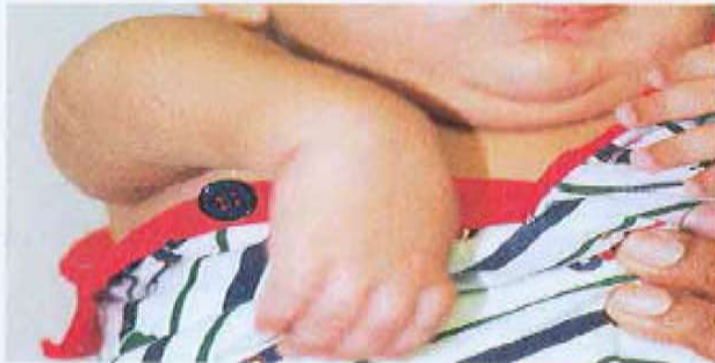
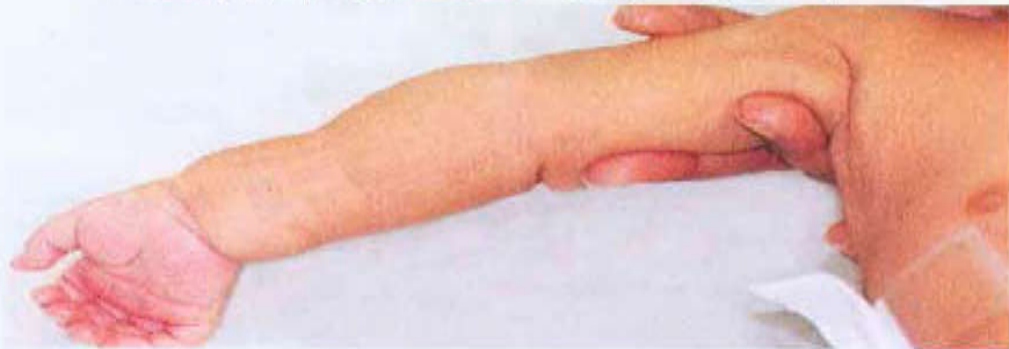
FIGURE 13

Wrist, fingers, Thumb: No flexion, no extension.



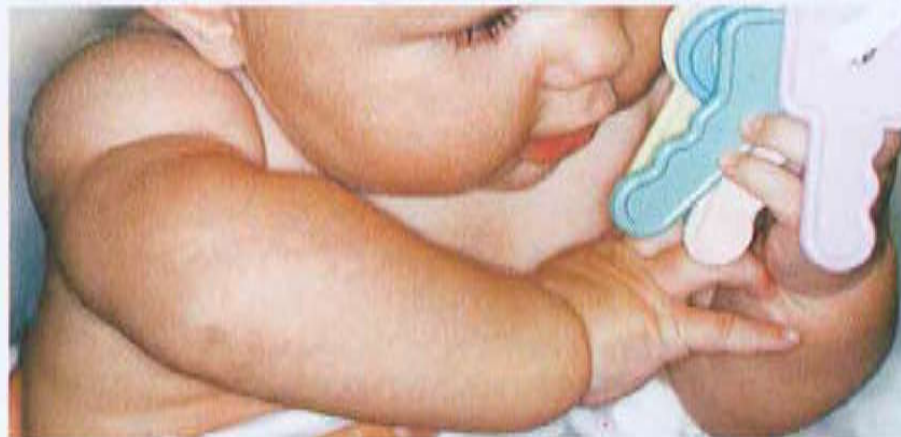
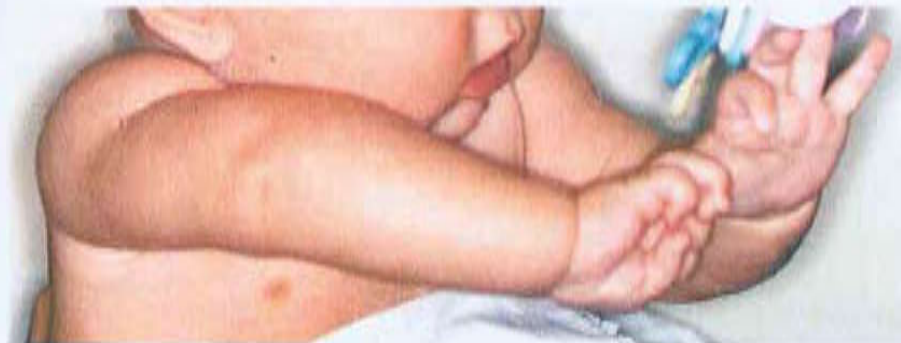
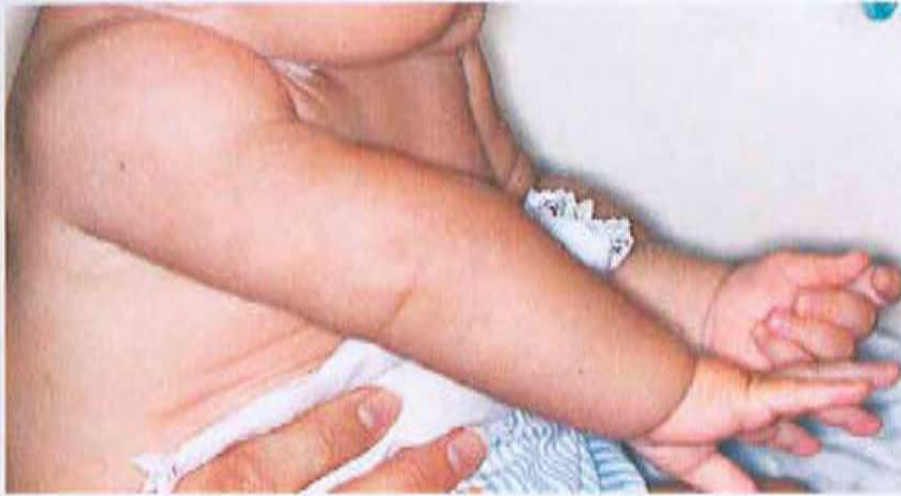FIGURE 14

Elbow flexion without biceps - Evaluation at 6 months - Elbow flexion is not the same as biceps function, Anterior shoulder flexion permits elevation of the elbow, allowing gravity to help the brachioradialis into some elbow flexion. Biceps is M1, deltoid M2, wrist extensor normal.